

The Use of Dermacell[®] in Fingertip Injury

Wu, Tsung-Hsuan¹, Giampietro Bertasi^{2,*}

¹Land Seed Hospital, Taiwan

²University of Padua, Italy

Abstract

Matrices or tissue scaffolds provide a collagen structure for tissue remodelling while the removal of viable cells aims to minimize or prevent inflammatory or immunogenic response.

Allograft collagen scaffold can support the patient's own cellular ingrowth, engineered to minimize an immune response and to yield a bio-compatible matrix and support incoming cellular growth. The decellularized dermis retains its growth factors, native collagen scaffold, and elastin, thanks to a LifeNet Health proprietary processing technology.

Corresponding author: Giampietro Bertasi, University of Padua

Citation: Wu, Tsung-Hsuan, Giampietro Bertasi (2019) The use of Dermacell[®] in Fingertip Injury. Journal of Clinical Case reports and Images - 1(2):14-22. <https://doi.org/10.14302/issn.2641-5518.jcci-19-2626>

Keywords: Finger tip injury, ADM, Dermacell

Received: Jan 26, 2019 **Accepted:** Mar 04, 2019 **Published:** Mar 14, 2019

Editor: Mohamed Elfahar, Pan-Arab Federation of Societies for the Surgery of the Hand, Egypt.

Introduction

Fingertip injuries are defined as those distal to the insertion of the flexor and extensor tendons. Primary goal of treatment is a painless fingertip with durable and sensate skin. [1] Methods of treatment include healing by secondary intention, skin grafting, shortening of the bone and primary closure, and coverage with local or regional flaps.

Evaluation

- History and mechanism of the injury
- Patient factors age, gender, handedness, occupation, and history of previous hand injuries
- Function of flexor and extensor tendons
- Rx
- Antibiotics and tetanus prophylaxis
- Soft-tissue loss without exposed bone
- Soft-tissue loss with exposed bone

- Amputation
- Nail bed injuries

Treatment

For the treatment of fingertip injuries, the decision making process should proceed from the simpler techniques to the more complicated. When no bone is exposed, the open method is ideal for small or moderate sized wounds, and skin grafting should be considered for larger wounds. Distal transverse and dorsal oblique amputations with bone exposure can be treated with local advancement flaps. [2] [3] [4] [5] [6] [7] [8] [9] [10] [11] [12] [13] [14]

Conclusion

Derma cell was able to provide protection for the wound while encouraging rapid healing without the disadvantages of donor site morbidity and increased patient pain from an autograft. The rapid wound closure was encouraging and supports further use of Derma Cell for treating soft tissue trauma wounds.

Case no. 1. 32 y/o, male. Crush injury with tip amputation of right middle finger. (Figure 1-4).

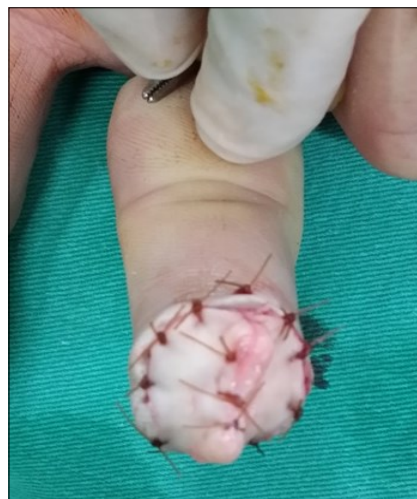
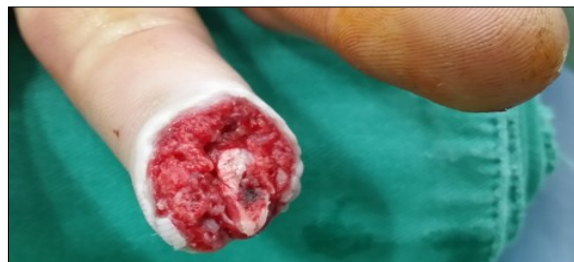
Figure 1. Post-op

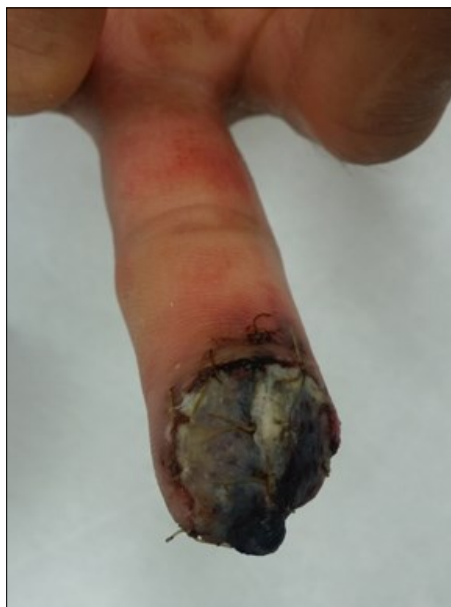

Figure 2. 4 days post-op

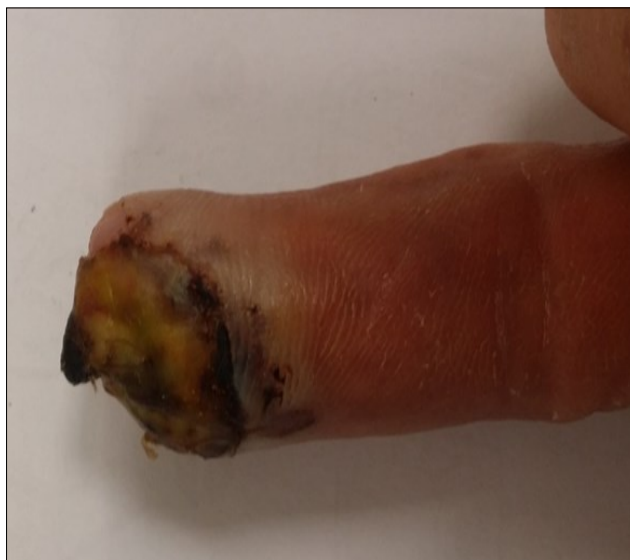

Figure 3. 2 wks postr-o

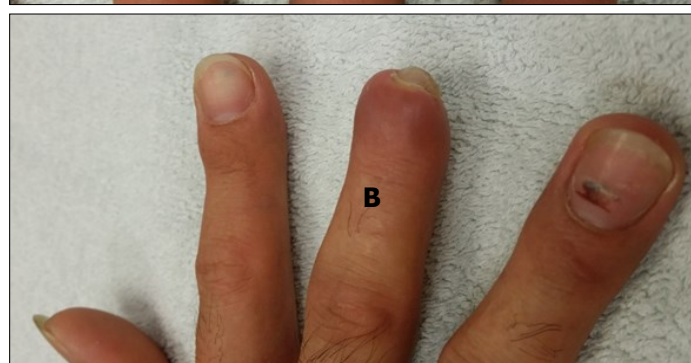
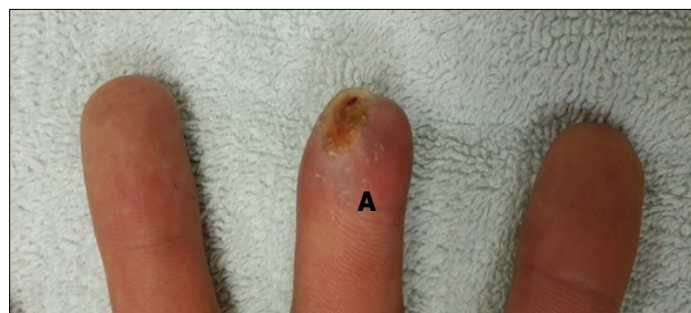
Figure 4. a-b: 4 wks post-op

Case no. 2. 48 y/o, female. Laceration wound of right index finger; dorsal oblique soft tissue defect; nail bed defect; over DIPJ with bone and joint exposure. (Figure 5-8).

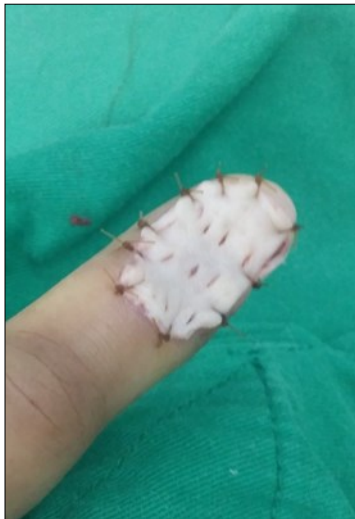
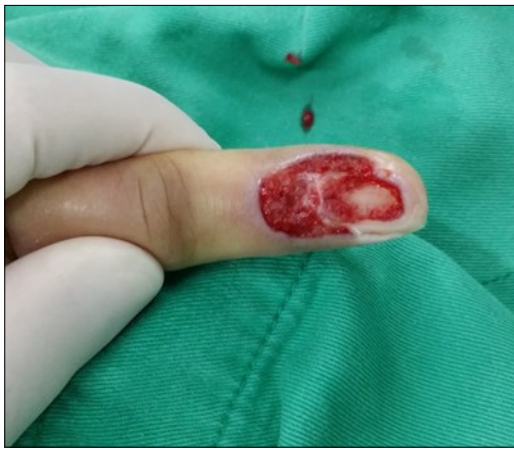
Figure 5. Post-op

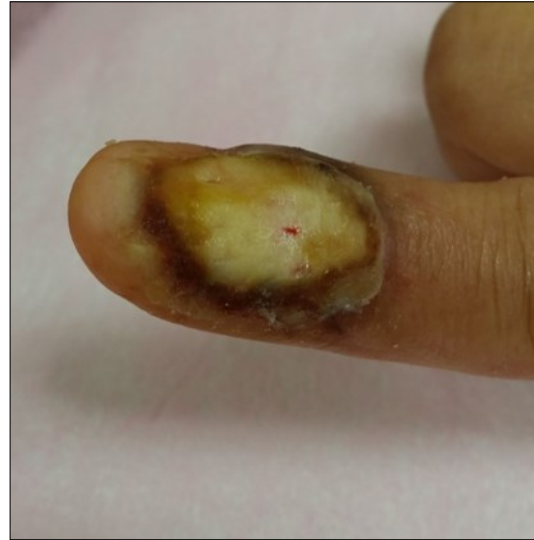

Figure 6. 4 wks post-op

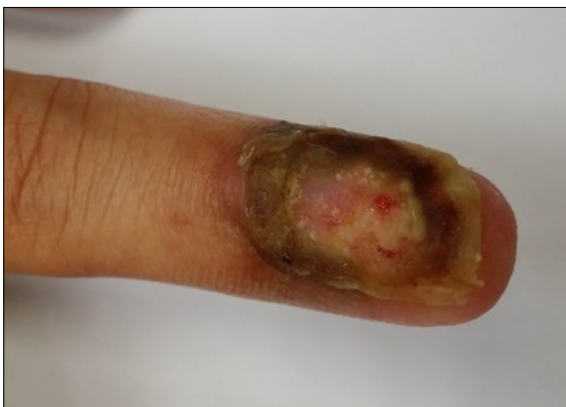

Figure 7. 8 wks post-op

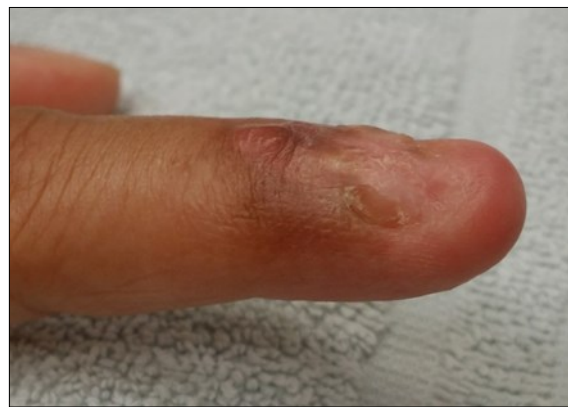

Figure 8. 11 wks post-op

Case no 3. 42 y/o, male. Crush injury with soft tissue defect of volar side of the left thumb. (Figure 9-13).

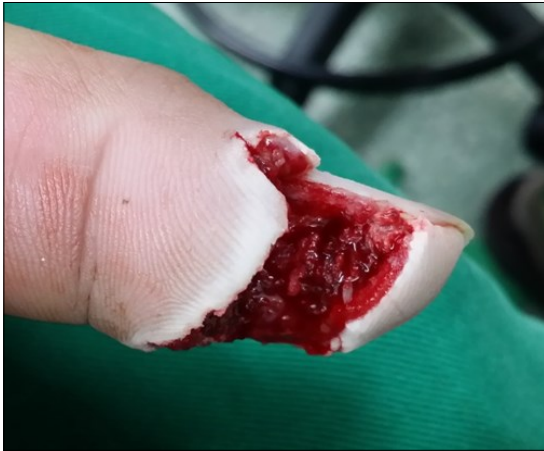

Figure 9. 4 days post-op

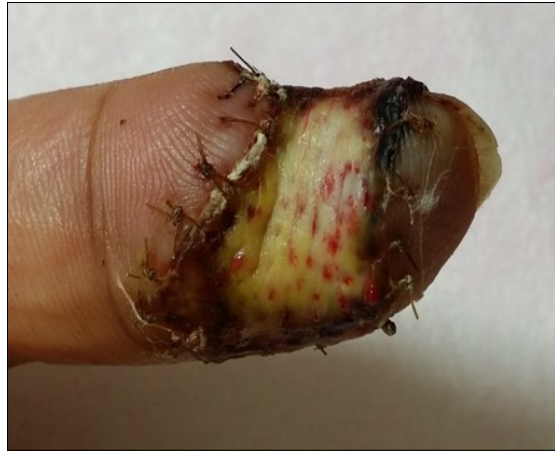

Figure 10. 15 days post-op

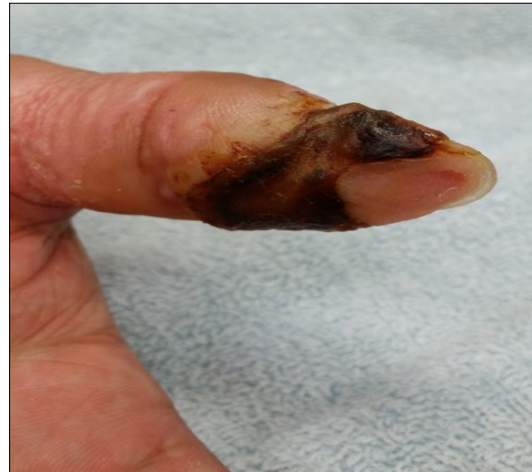

Figure 11. 2 months post-op

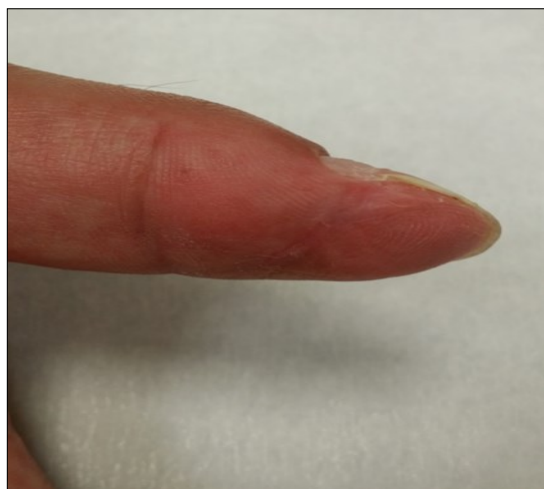

Figure 12. 3 months post-op

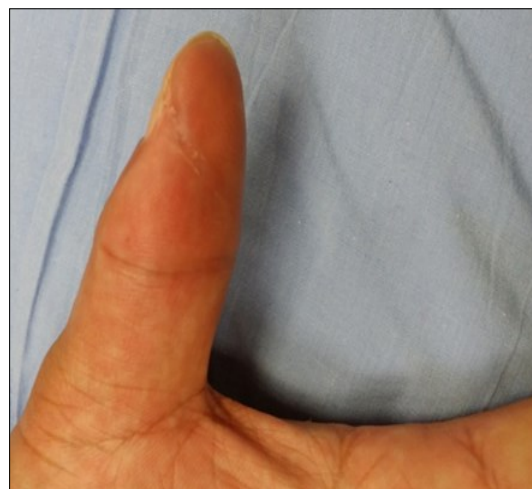

Figure 13. 4 months post-op

Case 4. 44 y/o female. Laceration wound of the left thumb; dorsal oblique soft defect; nail bed defect. Over DIPJ with bone and joint exposure. (Figure 14-15).

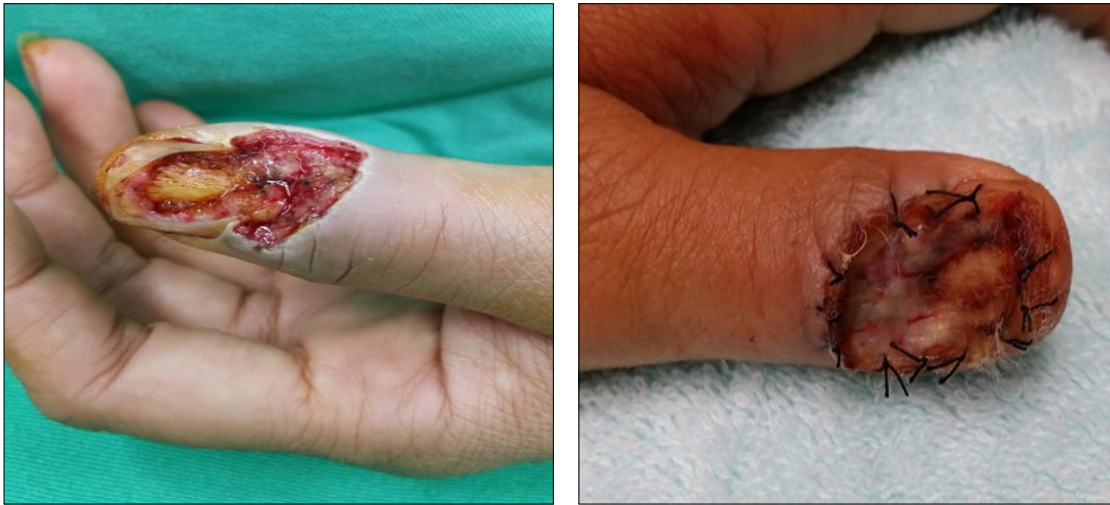

Figure 14. 4 days post-op

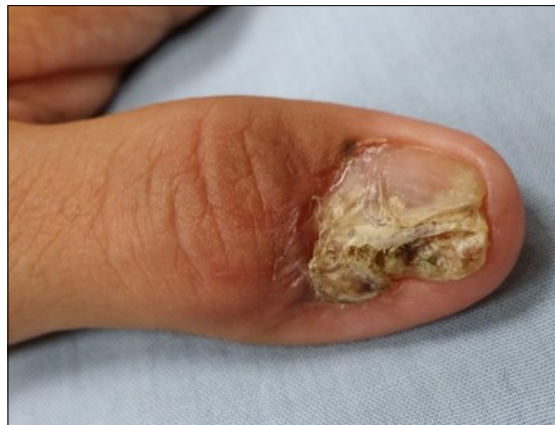

Figure 15. 3 months post-op

Case 5. 24 y/o male. Contact full thickness burn wound of right thumb; soft tissue defect of dorsal side of the IPJ; tendon exposure. (Figure 16-18)

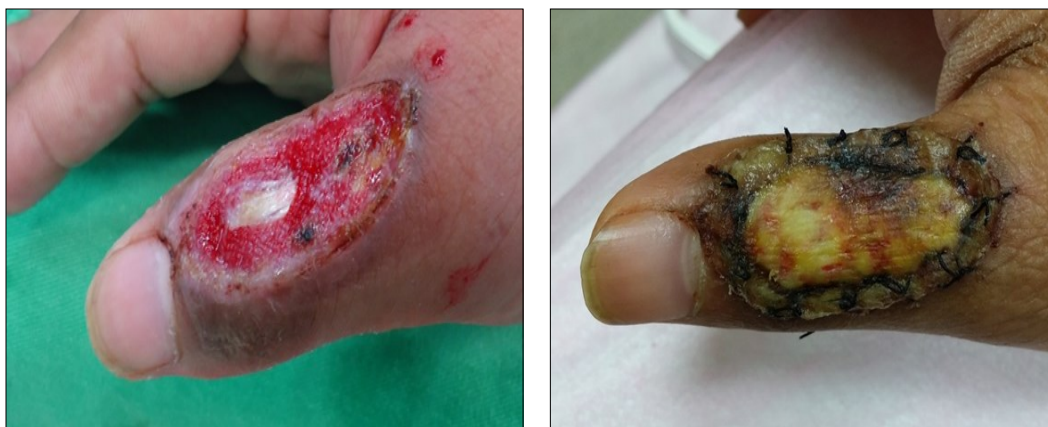

Figure 16. 2 weeks post-op

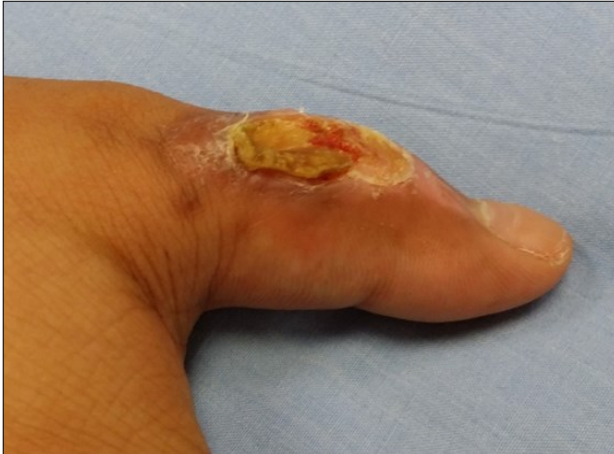

Figure 17. 6 weeks post-op

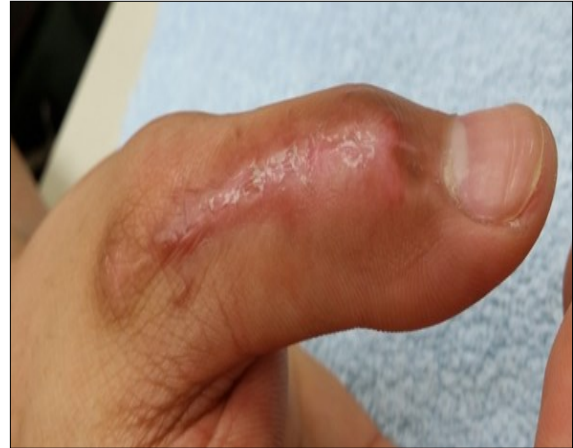

Figure 18. 10 weeks post-op

Case 6. 54 y/o male. Chemical burn, full thickness burn wound of right middle finger; tendon exposure. (Figure 19-21).

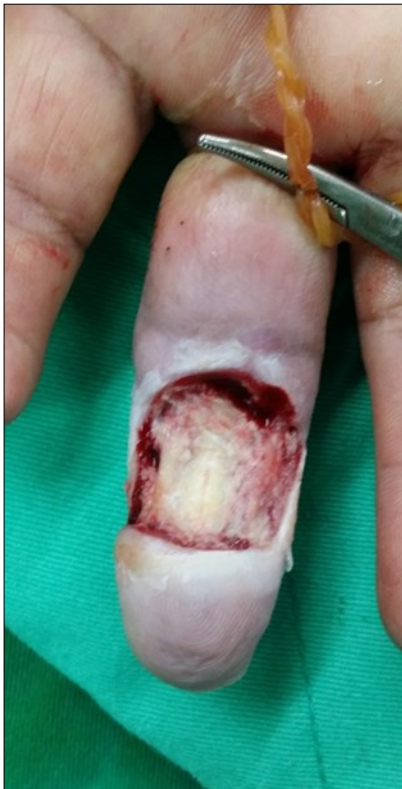

Figure 19. 8 days post-op

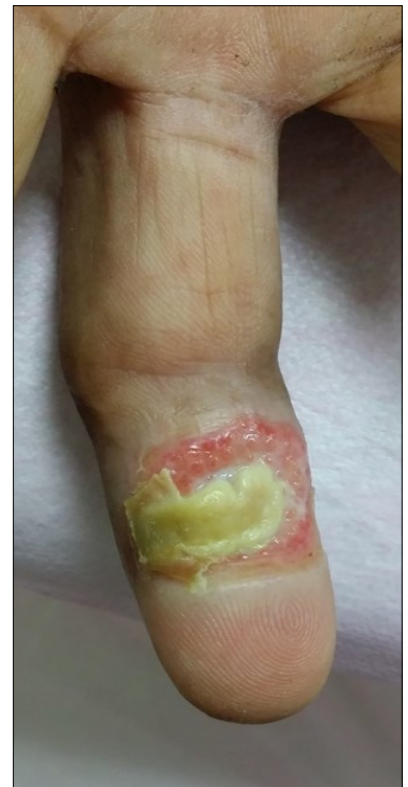
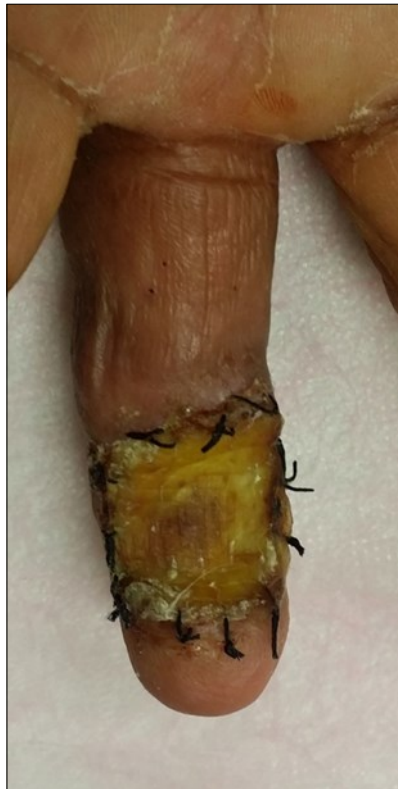
Figure 20. 2 months post-op

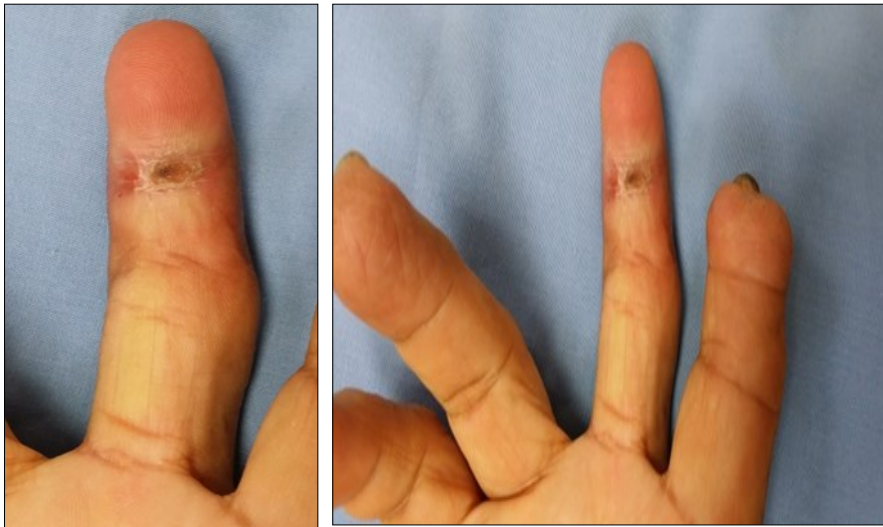


Figure 21. 4 months post-op

Case 7. 40 y/o female. Crush injury of the right hand; amputation of right middle finger through DIPJ with volar oblique defect; amputation of right finger through middle phalanx with volar oblique defect; bone exposure. (Figure 22-25).

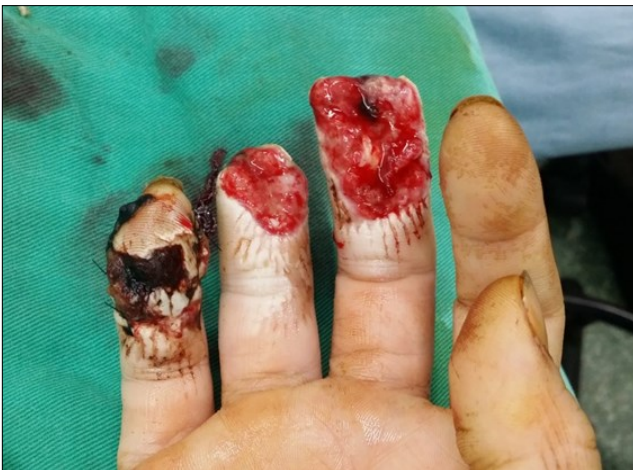

Figure 22. 8 days post-op

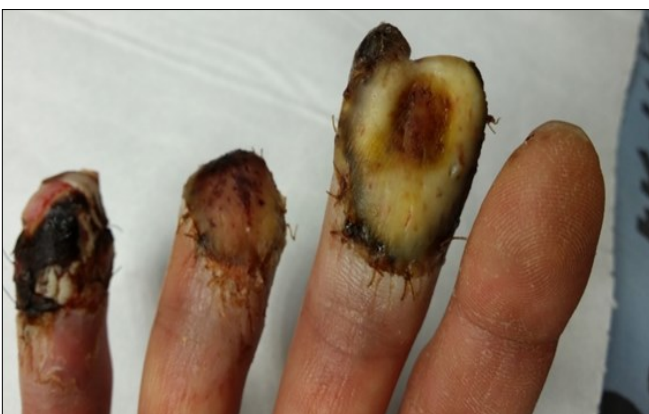
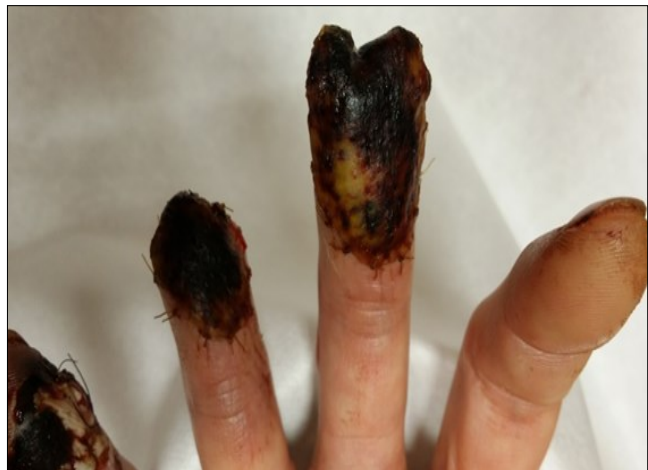
Figure 23. 2 weeks post-op

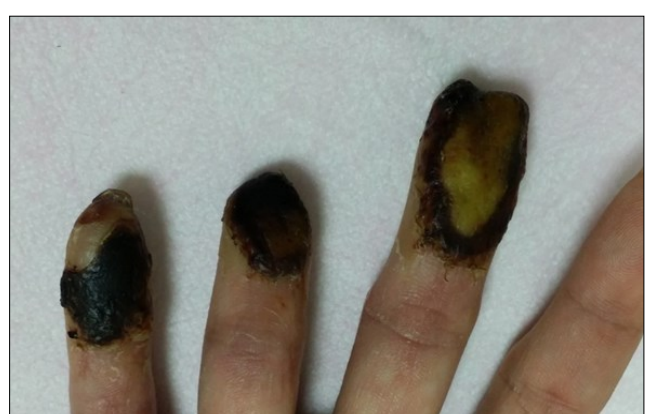

Figure 24. 2 months post-op

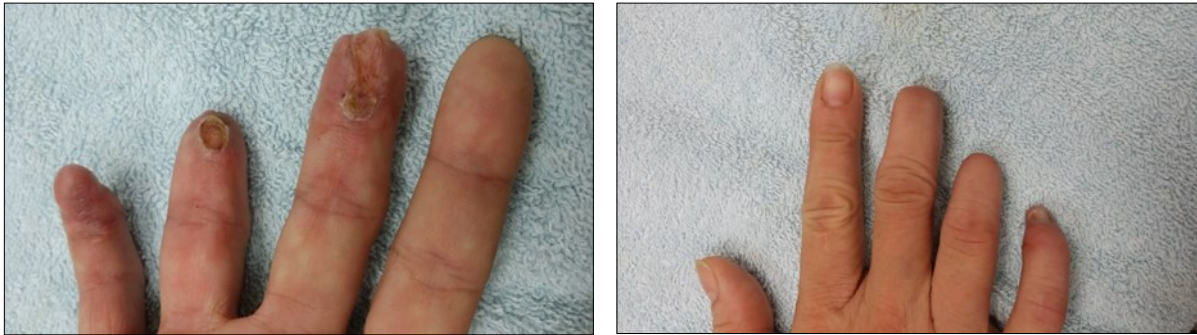


Figure 25. 3 months post-op

Result

The wounds progressed steadily, with full wound closure being achieved (average 1 to 4 months) after initial implantation. There were no signs of infection observed and the patient did not experience any reaction to the graft. Although the wound began healing slowly initially, the authors felt that was due to the complexity of the traumatic wound.

We Treat Routinely Finertip Injuries with ADM (Derma cell).

References

1. Zook EG: Anatomy and physiology of the perionychium. *Hand Clin* 1990;6:1-7.
2. Chow SP, Ho E: Open treatment of fingertip injuries in adults. *J Hand Surg [Am]* 1982;7:470-476.
3. Louis DS, Palmer AK, Burney RE: Open treatment of digital tip injuries. *JAMA* 1980;244:697-698.
4. Schenck RR, Cheema TA: Hypothenar skin grafts for fingertip reconstruction. *J Hand Surg [Am]* 1984;9:750-753.
5. Rosenthal EA: Treatment of fingertip and nail bed injuries. *Orthop Clin North Am* 1983;14:675-697.
6. Kappel DA, Burech JG: The cross-finger flap: An established reconstructive procedure. *Hand Clin* 1985;1:677-683.
7. Moberg E: Aspects of sensation in reconstructive surgery of the upper extremity. *J Bone Joint Surg Am* 1964; 46:817-825.
8. Gaul JS Jr: Radial-innervated cross-finger flap from index to provide sensory pulp to injured thumb. *J Bone Joint Surg Am* 1969;51:1257-1263.
9. Vlastou C, Earle AS, Blanchard JM: A palmar cross-finger flap for coverage of thumb defects. *J Hand Surg [Am]* 1985;10:566-569.
10. Russell RC, Van Beek AL, Wavak P, et al: Alternative hand flaps for amputations and digital defects. *J Hand Surg [Am]* 1981;6:399-405.
11. Littler JW: Neurovascular skin island transfer in reconstructive hand surgery, in Wallace AB (ed): *Transactions of the International Society of Plastic Surgeons*. London: E & S Livingstone, 1960, pp 175-178.
12. Van Beek AL, Kassan MA, Adson MH, et al: Management of acute fingernail injuries. *Hand Clin* 1990;6:23-35.
13. Zook EG, Guy RJ, Russell RC: A study of nail bed injuries: Causes, treatment, and prognosis. *J Hand Surg [Am]* 1984;9:247-252.
14. Shepard GH: Management of acute nail bed avulsions. *Hand Clin* 1990;6:39-58.