



Squamous Cell Carcinoma Of The Conjunctiva (Scc) And Human Immunodeficiency Virus (Hiv): What Reality In Ivory Coast Through 23 Cases?

Berete Coulibaly R^{1*}, Konan Abokan J.¹, Sowagnon Thierry Y C², Kouakou Kouassi S.¹, Fanny Adama¹.

1. Ophthalmology Department of University Hospital of Treichville

2. Ophthalmology Department of University Hospital of Yopougon

Abstract

Introduction: Squamous cell carcinomas of the conjunctiva (SCC) are rare neoplasia but have a high rate of increase and a high rate of mortality, especially when they occur in the context of Human Immunodeficiency Virus (HIV) infection. The objective of this study was to establish an epidemiological and clinical profile of SCC in patients living with HIV and to assess its evolutionary characteristics.

Patients and methods: this was a descriptive cross-sectional study carried out over a period of 5 years in the ophthalmology department of the University Hospital of Treichville. The data collected focused on epidemiological, clinical, pathological, therapeutic and evolutionary elements. Twenty tree eyes of 23 patients were examined during this period.

Results: The average age of our patients was 45 years with extremes ranging from 31 to 60 years. A female predominance was observed with a sex ratio of 0.92. The average consultation period was 18 months with extremes ranging from 6 to 60 months. Physically, 35% of our eyes (08 eyes) presented a functional loss of the eye. All our patients had a HIV positive status with 16 cases of HIV1 infection, 4 cases of HIV 2 infection and 3 cases of HIV 1 and 2 co-infection. Lymphocyte typing was performed for 15 patients out of the 23 With CD4 cell counts < 200 in 30.43% of cases, between 200 and 500 in 34.78% of cases. All our tumors had had biopsy excision with pathological examination. A postoperative adjuvant topical chemotherapy in 6 cases. The average follow-up period of our patients was 29 months. In all cases, it was invasive differentiated squamous cell carcinoma.

Discussion: HIV infection is a risk factor for the occurrence of conjunctival squamous cell carcinoma, but it is also an aggravating factor especially in the case of low CD4 cell count, particularly in sub-Saharan Africa, where the fight against infection, although boosted in these recent years, is far to achieve all objectives

Conclusion: HIV seroprevalence is very often associated with opportunistic infections which include carcinogenic processes such as squamous cell carcinomas of the conjunctiva

Corresponding author : Coulibaly Rokia BERETE, Senior Lecturer of Ophthalmology Department, University Hospital of Treichville BP V3 Abidjan Ivory Coast, E-mail berete1rokia7@gmail.com, bereterokia@hotmail.fr

Keywords: squamous cell, carcinoma, HIV-AIDS, lymphocytes CD4, Treichville

Received : Jul 05,2017

Accepted: Sep 20,2017

Published: Sep 28,2017

Introduction:

The epidemic of HIV infection in sub-Saharan Africa, which bears the greatest burden, represents at least 70% of infected persons for 11% of the world's population, 75% of deaths and 90% of infections in children [1,2]. A HIV-infected person may remain asymptomatic for 2 to 10 years or more. The occurrence of opportunistic infections in general is related to a significant decline in immune defenses and an increase in the viral load defining AIDS [3]. Conjunctival squamous cell carcinoma like all tumor diseases presents itself as an opportunistic infection. A classification of the CDC 1993 determines a correlation between the CD4 cell count and the clinical course of AIDS [4]. Unfortunately, in sub-Saharan Africa, particularly in Côte d'Ivoire, it is not easy to get the assay of CD4 cell count in patients living with HIV who arrive in hospitals completely impoverished. In our study only 27 out of 54 patients were able to perform the assay of CD4 cell count.

The objective of our study is to establish an epidemiological and clinical profile of squamous cell carcinoma of conjunctiva (SCC) in patients living with HIV and to assess its evolutionary characteristics in these HIV positive subjects.

Patients and Methods:

We carried out a descriptive cross-sectional study over a period of 4 years from January 2012 to December 2016 in the ophthalmology department of the University Hospital of Treichville. It involved 23 patients.

This study included HIV positive patients who consulted during the period and presented a conjunctival tumor with or without local-regional and cerebral invasion and with a histological diagnosis of epidermoid carcinoma. The data collection included the following elements of the history (age, gender, onset of the symptomatology, Personal and family history), clinical signs and evolution, ophthalmological and radiographic (tomodensitometry) elements.

The pathological diagnosis is obtained after analysis of biopsy incision fragment or surgical excision specimen and enucleation or even exenteration. All surgical procedures are performed under general anesthesia. Samples were fixed with formalin before being sent to the pathology department. HIV-AIDS serology was performed after informed consent of

patients, in some cases with the typing of CD4-lymphocytes. Adjuvant or neoadjuvant topical or general chemotherapy has sometimes been used. The statistical analysis was carried out by the Epi-info version 6.0 Software and a statistical comparison using the Chi2 test with a significance threshold set at 5%.

Results:

Epidemiological Results

The average age of our patients was 45 years with extremes ranging from 31 to 60 years. A female predominance was observed with a sex ratio of 0.92 (Table 1). All patients were black and lived in Abidjan (sub-Saharan Africa).

Table 1: Age group and Gender

	Age group				Gender	
	<25 years	25-45 years	46-65 years	>65 years	Male	Female
Effective	0	11	12	0	11	12
Percentage	0%	48%	52%	0%	48%	52%
Total	23 (100%)			23 (100%)		

Clinical Results

The average consultation period was 18 months with extremes ranging from 6 to 60 months. Our patients were seen in 70% and 30% respectively for an orbital tumor with exophthalmos and for a conjunctivo-lymbic tumor (Table 2, Figure 1, Figure 2). The involvement generally concerned the right eye in 78% of cases that is 18 eyes. Physically, 35% of our eyes (8 eyes) presented a functional loss of the eye (absence of luminous perception)(table 2).

Table 2 :Clinical appearance

	Clinical appearance presentation				Visual acuity	
	Ocular and orbit tumor	Exophthalmia	Conjunctivitis tumor	Necrosis tumor	>PL+	PL-
Effective	7	4	8	4	15	8
Percentage	31%	17%	35%	17%	78%	22%
Total	23 (100%)			23 (100%)		

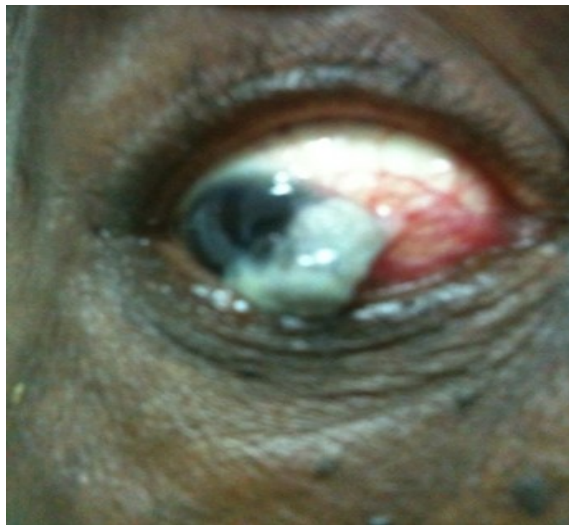

Figure 1 Localized form of conjunctival squamous cell carcinoma

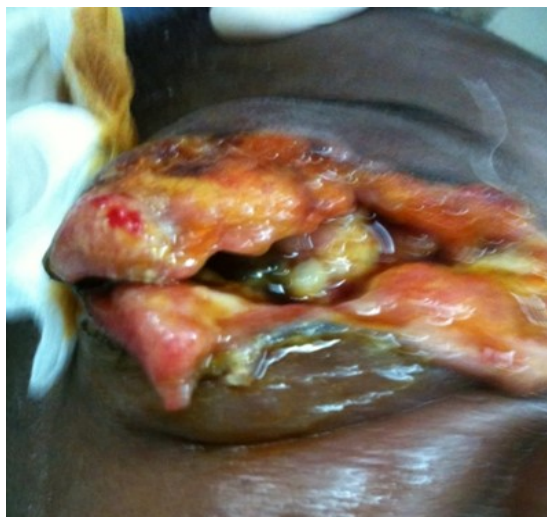

Figure 2: Invasive form of squamous cell carcinoma with exophthalmos

HIV status:

All our patients had a positive HIV status with 16 cases of HIV1 infection, 4 cases of HIV 2 infection and 3 cases of HIV 1 and 2 co-infection (Table 3). Lymphocyte typing was performed for 15 patients out of the 23 that is 65.21% with CD4 count < 200 in

Table 3: VIH Statut and CD4 Lymphocyte types

Ef- fecti ve	VIH Statut			CD4 Lymphocyte types			
	VIH1	VIH2	VI- H1et 2	<200	200- 500	>500	Un- specif ied
	16	4	3	7	8	0	8
Per- cent age %	69,6 %	17,4 %	13%	30,4 %	34,8 %	0%	34,8 %

30.43% of cases, between 200 and 500 in 34.78% of cases. The mean CD4 cell count was estimated to be 131 elements / ml (Table 3).

Management:

Most tumors underwent a biopsy excision with pathological examination of the surgical specimen. Six patients were treated with adjuvant chemotherapy

Pathological findings:

All 23 patients presented invasive differentiated squamous cell carcinoma (Figure 3). None in situ carcinoma was found.

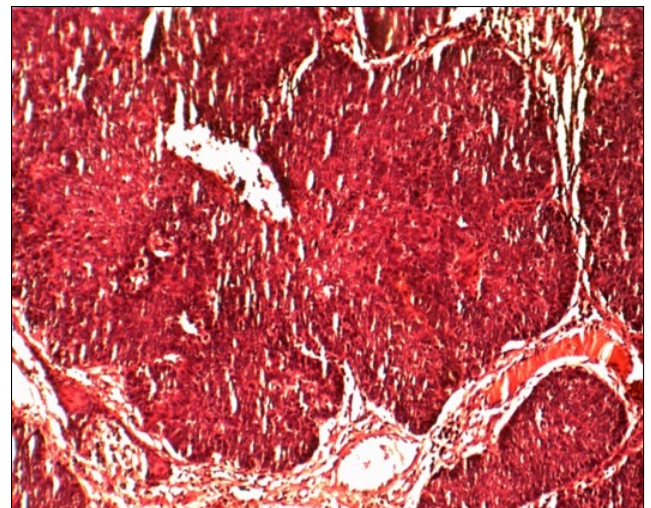


Figure 3 : Immature Squamous cell carcinoma, Hématein Eosin Coloration (HEX100): Epidermoid growth pattern without k ratization

Follow up:

The average follow-up was 18 months. Six patients underwent chemotherapy in register of cancer (cancerology). We noted five cases of recurrence, 8 were lost to follow-up (35%) and 3 deaths occurred during the study.

Discussion:

Squamous cell carcinoma of conjunctiva has also been found to occur in patients aged less than 50 years of age. This is also shown in your study [5]. We did not find any real gender predominance (sex ratio in the literature is 1) [6], although in our study the sex ratio was in favor of the female gender with 0.92 that is 52%. Several authors, including Imdary [7] and Caujolle [8], have found a male predominance. This finding in

sub-Saharan Africa could be explained by the tendency to feminize HIV infection with 6.4% compared to 2.9% of seroprevalence in humans [9]. Indeed, HIV infection as well as prolonged solar exposure and HPV (human papilloma virus) infection are unanimously recognized as risk factors [10] especially in tropical Africa. This female population represents the population most exposed to all kinds of abuses (sexual, polygamous and agricultural activities..) in Africa where they assist men to this day. This observation of the predominance of the female sex in the occurrence of the SCC in HIV-positive subjects was also made by Kaimbo Wa Kaimbo et al. [11] in the Congo and by Makupa et al. [12] in Tanzania who found 70% and 62.2%, respectively. HIV induces chronic suppression of the immune system, hence anti-cancer immunity, which increases the oncogenic potential especially in cases of dysplasia [13,14]. Moreover, this acquired immunosuppression is responsible for severe forms of SCC. In our study 70% of patients were seen with orbital tumor associated exophthalmos and 35% of eyes present functional eye loss. Indeed, the prevalence of SCC in patients living with HIV according to Chisi et al [15] is 7.8% in Kenya. In our study we were unable to establish this prevalence, however a large majority of patients received in consultation were HIV-positive, which immediately introduced a bias in our sampling. The severity of the clinical forms is correlated with a low CD4 cell count. According to Place et al., Bekele S. and al.[16,17], squamous cell carcinoma would occur early in patients living with HIV, and when this status is associated with a low CD4 cell count, the prognosis would prove to be poor because these patients seem to succumb to their HIV status rather than squamous cell carcinoma. This important immune depression would be related to a delayed diagnosis, a denial of the disease and the increased precariousness of the populations which creates a brake on their management. As for the influence of the type of HIV on the forms, our study did not establish a correlation between the severity of the forms of SCC and the serotype. On the other hand, we have noted, as in the literature, a clear predominance of HIV 1 on the associated forms and on HIV 2. Indeed, according to a UN-AIDS report, HIV 1 is the dominant serotype in sub-Saharan Africa where more than 2/3 of HIV-infected patients are infected with HIV 1.

The severity of clinical and histopathological forms made the management difficult in our context without, cryotherapy, radiotherapy. Most tumors underwent a biopsy excision with pathological examination of the surgical specimen. Six patients were treated with adjuvant chemotherapy. Other treatments have been proposed in the literature and appear to have a beneficial effect: Interferon alpha-2a as alternative treatment[18], chemoreduction of the tumor prior to surgery in advanced cases with orbital extension [19] fractionated strontium-90 radiation in a population with a high prevalence of HIV[20].

The prognosis remains reserved with 5 cases of recurrence, 3 cases of death. The average follow-up was 18 months. Six patients underwent chemotherapy in register of cancer (cancerology). We noted five cases of recurrence, 8 were lost to follow-up (35%) and 3 deaths occurred during the study. The prognosis of SCC remains poor in our study. The patients who died on adjuvant chemotherapy course had a very involves forms (figure 2) with positive surgical margin. In addition they were VIH positive with CD4 rate below 200 cel/mm³. Penolope found higher death rates with 26 patients evaluated over 6 years, therefore, study noted low rate of lost to follow up[21]. In this study we can established relationship between SCC extended forms and rate low rate of CD4 lymphocyte.

Conclusion:

HIV epidemic contributes to the occurrence of a variety of so-called opportunistic infections such as cancer diseases among which conjunctival squamous cell carcinoma is readily mentioned and whose severity would be correlated with the level of CD4 lymphocytes. The prevention of invasive SCC involves sensibilization, screening of patients with suspicious of conjunctival tumors and above all, localized SCC confirmed must be taken care optimally.

Conflict Interest

The authors reported declared that they have no competing interests

Abreviation:

Squamous Cell Carcinoma = SCC
Human Immunodeficiency Virus = HIV
Human Papilloma Virus = HPV
Light perception = PL

References :

1. Amat – Roze JM, Dumont GF. Le sida et l'avenir de l'Afrique. **Ethique**, 1994; 12(2) : 36 – 60.
2. Amat – Roze JM. L'infection à VIH/ Sida en Afrique subsaharienne, propos géographique. **Hérodote**, 2003 Avril; 111 : 115 – 17
3. Ouédraogo SM, Ouédraogo M, Dagnan NS, Adom AH. Infections opportunistes au cours du Sida au CHU de Treichville. **Mali Médical**, 2007; 22(2) : 26 – 28.
4. Bissagnene E., Die Kacou H, Aoussi Eba F. Guide diagnostique et thérapeutique de l'infection à VIH en Afrique. **Edition Gut**, Abidjan 1999 : 120 p
5. CR Berete, L Desjardins, LJ Kouassi, F Coulibaly, KS Kouakou et al. Relation entre le virus de l'immunodéficience acquis (VIH-sida) et carcinoma épidermoïde conjonctival (CEC) : étude épidémioclinique de 26 dossiers au service d'ophtalmologie du CHU de Treichville (Abidjan-Côte d'Ivoire). **J Fr Ophtalmol**, 2016; 39: 467-73
6. Acis D, Donnio A, Ayeboua L, Richer R, Guyomarch J. et al. Carcinome épidermoïde conjonctival : à propos de 4 cas aux Antilles. **J Fr Ophtalmol**, 2008; 31 : 533-7
7. Imdamy I, Soufi G, El Berdaouin, Chefchaouni MC, Abdellah El et al. Prise en charge des carcinomes épidermoïdes conjonctivaux : à propos de 41 cas. Congrès 2011
8. Caujolle JP, Maschi C, Chauvel P, Herault J, Gastaud P. Surgery and additionnel protontherapy for treatment of invasive and recurrent squamous cell carcinomas : technique and preliminary results. **J Fr Ophtalmol**, 2009 Déc; 32(10): 707-14.
9. NS Dagnan, I Tiembré, J B B Vroh, B Diaby, P Zengbe- Acray et al. Seroprévalence de l'infection à VIH en conseils et dépistage volontaire par stratégie mobile en zone rurale en Côte d'Ivoire. **Santé publique**, 2013; vol 25
10. Ateenyi- Agaba. Conjunctival squamous- cell carcinoma associated with HIV infection in Kampala, Uganda. **Lancet**, 1995 Mar 18; 345(8951): 695-6.
11. Kaimbo Wa Kaimbo D, Parys-Van Gingerdeuren R, Missoten L. Conjunctival squamous cell carcinoma and intraepithelial neoplasia in AIDS patients in Congo-Kinshasa. **Bull Soc Belge Ophtalmol**, 1998; 268: 135-41.
12. Makupa II, Swai B, Makupa WU, White VA, Lewallen S. Clinical factors associated with malignancy and HIV status inpatients with ocular surface squamous neoplasia at Kilimanjaro Christian medical centre, Tanzania. **Br J Ophthalmol**, 2012; 96: 482- 4.
13. Dalton-Griffin L, Kellam P. Infectious causes of cancer and their detection. **J Biol**, 2009;8:67.
14. Verma V, Shen D, Sieving PC, Chan CC. The role of infectious agents in the etiology of ocular adhexal neoplasia. **Surv Ophthalmol**, 2008; 53: 312- 31.
15. Chisi SK, Kollmann MK, Karimurio J. Conjunctival squamous cell carcinoma in patients with human immunodeficiency virus infection seen at two hospitals in Kenya. **East Afr Med J**, 2006 Mai;83 (5):267-70.
16. Place RJ, Gregorcyk SG, Huber PJ, Simmang CL. Outcome analysis of HIV-positive patients with anal squamous cell carcinoma. **Dos Colon Rectum**, 2001 Avril; 44(4): 506 – 12.
17. Bekele S, Gelaw Y, Tessema F. Ocular manifestation of HIV/AIDS and correlation with CD4+ cells count among adult HIV/AIDS patients in Jimma town, Ethiopia: a cross sectional study. **BMC Ophthalmol**. 2013 May 27;13:20. doi: 10.1186/1471-2415-13-20.
18. Cruzado-Sánchez D, Salas-Diaz M, Tellez WA, Alvarez-Matos SE, Serpa-Frias S. Interferon alpha-2a as alternative treatment for conjunctival squamous cell carcinoma. **Arch Soc Esp Oftalmol**. 2017 May 15. pii: S0365-6691(17)30125-9. doi: 10.1016/j.oftal.2017.03.006.[Epub ahead of print].
19. Akshay Gopinathan Nair, Swathi Kaliki, Dilip Kumar Mishra, Vijay Anand Reddy, Milind N Naik. Neoadjuvant chemotherapy for invasive squamous cell carcinoma of the conjunctiva: A case report. **Indian J Ophthalmol**. 2015 Dec; 63(12): 927–929. Doi:10.4103/0301-4738.176026.
20. Lecuona K, Stannard C, Hart G, Rice J, Cook C, Wetter J, Duffield M. The treatment of carcinoma in situ and squamous cell carcinoma of the conjunctiva with fractionated strontium-90 radiation in a population with a high prevalence of HIV. **Br J Ophthalmol**. 2015 Sep;99(9):1158-61. doi: 10.1136/bjophthalmol-2014-306327. Epub 2015 Mar 17.
21. Penelope A McKelvie, Mark Daniell, Alan McNab, Michael Loughnan. Squamous cell carcinoma of the